

COMPANION OR PET ANIMALS

Favourable long-term outcome of granulomatous colitis involving two *Escherichia coli* strains with multiple antimicrobial resistances in a French bulldog in Germany

Maximilliane Mueller,¹ Dorothee Petra Dahlem,¹ Manfred Henrich,² Reto Neiger,¹ Silke Schmitz¹

¹Small Animal Clinic, Justus-Liebig University, Giessen, Hessen, Germany
²Institute for Veterinary Pathology, Justus-Liebig-Universität Giessen Fachbereich Veterinärmedizin, Giessen, Hessen, Germany

Correspondence to

Dr Reto Neiger,
reto.neiger@vetmed.uni-giessen.de

Received 20 January 2016

Revised 17 March 2016

Accepted 6 April 2016

SUMMARY

A two-year-old female French bulldog was presented for chronic large bowel diarrhoea. The dog had been suspected to have granulomatous colitis, but no improvement was noted with enrofloxacin treatment. Diagnosis was confirmed by histology and fluorescent in situ hybridisation. Isolated *Escherichia coli* strains showed multiple resistances to antimicrobials, including enrofloxacin. Treatment with potentiated amoxicillin and cefovecin resulted in complete resolution of clinical signs within two weeks and treatment was continued for a total of eight weeks. The dog had no signs of large bowel diarrhoea and gained 2 kg of bodyweight within 10 months. This is the first case report of a French bulldog with granulomatous colitis with a favourable long-term outcome despite colonisation with multiresistant adherent-invasive *E coli*. This case highlights the importance of antimicrobial sensitivity testing from colonic mucosal biopsy samples in canine granulomatous colitis. It should raise awareness of this disease in continental Europe.

BACKGROUND

Canine granulomatous colitis (GC), previously also known as histiocytic ulcerative colitis, is characterised by chronic large intestinal diarrhoea, severe tenesmus, haematochezia, pain and weight loss. The disease has predominantly been reported in boxer dogs less than four years of age (Churcher and Watson 1997, Craven and others 2011). It was long suspected to have an infectious cause, as it resembled Whipple's disease in human beings (Van Kruiningen and others 1965, Afshar and others 2010), especially as clinical remission in response to antibiotic therapy was documented (Hostutler and others 2004). Later investigations showed that both dysregulation of local immune responses (likely genetic in origin) and bacterial agents were involved in the development of canine GC (Simpson and others 2006). *Escherichia coli* strains which resemble adherent-invasive *E coli* (AIEC) detected in a subset of human beings with Crohn's disease (Darfeuille-Michaud and others 2004) have been documented in mucosal biopsies from dogs with GC (Simpson and others 2006). Initially, dogs with GC responded well to treatment with enrofloxacin, but antimicrobial resistance is increasingly reported. Treatment failure is becoming more

common; and antimicrobial resistance is associated with poor outcome (Craven and others 2010).

Since the first reports in boxer dogs, several single case reports and small case series of GC have also been described in other breeds, mainly French bulldogs (Stokes and others 2001, Tanaka and others 2003, Manchester and others 2013), but also in a mastiff, Alaskan malamute, doberman, English bulldogs and two beagle dogs (Stokes and others 2001, Hostutler and others 2004, Carvalho and others 2015). Overall, the disease has predominantly been described in the USA, with single cases in Japan, Australia, Brazil and Europe (Van der Gaag and others 1978; Churcher and Watson 1997, German and others 2000, Tanaka and others 2003, Krafft and others 2010, Pavarini and others 2011, Manchester and others 2013).

Here the authors report the first case of GC in a French bulldog from Germany with a favourable long-term outcome despite multidrug antimicrobial resistance of the isolated *E coli* strains.

CASE PRESENTATION

A two-year-old entire female French bulldog was referred to the Small Animal Clinic for investigations into large bowel diarrhoea of 18 months duration. The diarrhoea had progressed from soft to watery stools with an increased defaecation frequency to daily haematochezia with severe tenesmus and dyschezia. Additionally, weight loss of approximately 1.5 kg (14 per cent of the dog's total bodyweight) and inappetence were noted for four weeks before presentation. Previous treatments included feeding of a hydrolysed protein diet (z/d, Hill's), and the administration of fenbendazole (Panacur; MSD; 50 mg/kg once a day for three days) and enrofloxacin (Baytril; Bayer; 10 mg/kg every 24 hours for six weeks). When no improvement was noted, metronidazole (Clont; INFECTOPHARM; 10 mg/kg every 24 hours for 14 days) had been prescribed, which also did not resolve or improve clinical signs.

INVESTIGATIONS

On physical examination the dog presented with a body condition score of 4/9 (11.8 kg), was moderately subdued but responsive with no abnormalities of cardiovascular parameters and a normal rectal body temperature. Digital rectal manipulation



CrossMark

To cite: Mueller M, Dahlem DP, Henrich M, et al. *Vet Rec Case Rep* Published online: [please include Day Month Year] doi:10.1136/vetreccr-2016-000296

Veterinary Record Case Reports

elicited moderate pain and a slightly irregular mucosal surface was palpated. The canine chronic enteropathy clinical activity index (CCECAI) indicated severe disease (17 points; with >12 considered severe) (Jergens 2004). Faecal examination (sedimentation/flotation and Giardia antigen ELISA) had been performed several times before referral and consistently yielded negative results; thus it was not repeated.

Complete blood count (ADVIA 2120 automated haematology analyser, Siemens Healthcare Diagnostic, Eschborn, Germany) revealed moderate leucocytosis ($17.8 \times 10^9/l$; reference interval (RI) $5.5\text{--}13.7 \times 10^9/l$) with mild mature neutrophilia ($13.5 \times 10^9/l$; RI $2.8\text{--}8.7 \times 10^9/l$) and mild monocytosis ($2.1 \times 10^9/l$; RI $0.1\text{--}0.8 \times 10^9/l$), which was interpreted as a stress leucogram. Serum biochemistry showed mild hypoalbuminaemia (28.6 g/l; RI 29.6–37.0 g/l) as the only abnormality. Serum cobalamin concentration was determined to assess possible malabsorption/small intestinal involvement, especially as weight loss was part of the dog's problems, and was 399 pg/ml (RI 300–800 pg/ml). Serum trypsin-like immunoreactivity was not determined and no adrenocorticotrophic hormone (ACTH) stimulation test was performed, as both exocrine pancreatic insufficiency and hypoadrenocorticism were considered extremely unlikely causes of the dog's clinical signs.

On abdominal ultrasonography, moderate mesenteric lymphadenopathy without change in echotexture or structure of the lymph nodes, and severe transmural thickening of the colon were detected (Fig 1). These changes were considered consistent with an infiltrative process of the colonic wall. Inflammation seemed more likely due to the early onset and long duration of clinical signs, even though neoplasia (especially alimentary lymphoma) could not be ruled out at this stage. After a 48-h fast and three warm-water enemas, proctoscopy/colonoscopy was performed under general anaesthesia using a flexible endoscope (9 mm diameter; Pentax EG2730K, Germany). Macroscopically, the colonic mucosa appeared moderately hyperaemic and oedematous, with a severely irregular and rigid surface, making air insufflation during endoscopy and appropriate visualisation extremely difficult. Visualisation of the ileocaecal valve or intubation of the ileum was not possible. Eight colonic mucosal pinch biopsies were obtained for histopathology. Two additional biopsies were immediately transferred to 2 ml Eppendorf tubes containing fresh sterile LB broth

(Sigma-Aldrich Chemie GmbH, Munich, Germany) for bacterial culture. Colonoscopy was followed by a survey gastroduodenoscopy to ensure no gross lesions were missed in the accessible part of the upper gastrointestinal tract. Ten pinch biopsies each were obtained from the duodenum and from the stomach, respectively, for histopathological examination.

Histopathological assessment of gastric and duodenal mucosal biopsies revealed no architectural changes but mildly increased numbers of lymphocyte and plasma cell counts within the lamina propria (according to Day and others 2008). Colonic mucosa samples demonstrated a large number of macrophages with granular cytoplasm as well as lesser numbers of neutrophils, lymphocytes, plasma cells and eosinophils within the lamina propria. The majority of colonic crypts were effaced and obscured by the infiltration. The remaining crypts were mildly dilated; the overlying epithelium was extensively ulcerated with accumulation of neutrophils, lymphocytes and plasma cells, and the formation of granulation tissue (Fig 2). Periodic acid-Schiff (PAS) staining of colonic biopsies confirmed the presence of PAS-positive macrophages within the mucosa and hence led to the tentative diagnosis of GC (Fig 3).

For fluorescence in situ hybridisation (FISH), formalin-fixed and paraffin-embedded colonic biopsy samples were mounted on coated glass slides and sent to a laboratory specialised in the identification of bacteria within formalin-fixed tissues in dogs (Kenneth Simpson Laboratory, Cornell University, Ithaca, New York, USA) (Simpson and others 2006). Using eubacterial hybridisation probes, invasive bacteria could be identified within the inflamed mucosa.

Bacterial culture of colonic biopsies yielded two different *E coli* strains (*E coli* 1 and *E coli* 2) by their macroscopic appearance and antimicrobial resistance pattern. The combination of FISH and culture results confirmed the diagnosis of GC (Fig 4).

Both *E coli* strains were resistant to most tested antimicrobials (Table 1). In vitro sensitivity towards potentiated amoxicillin, gentamicin, amikacin and polymyxine B for strain 1, and to cephalaxin, cefovecin, gentamicin, amikacin, and polymyxine B for strain 2 was identified. Based on this antimicrobial resistance pattern, these strains were classified as suspicious for an extended spectrum β -lactamase (ESBL) resistance profile.

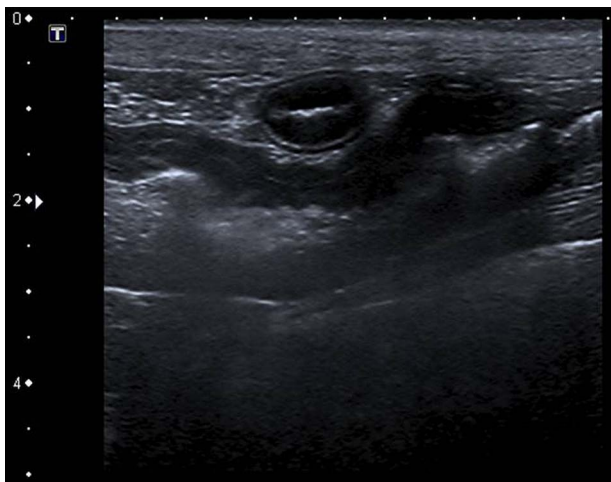


FIG 1: Ultrasonographic picture of the longitudinal axis of the descending colon wall shows irregular diffuse transmural thickening, with a wall thickness of 3.5 mm

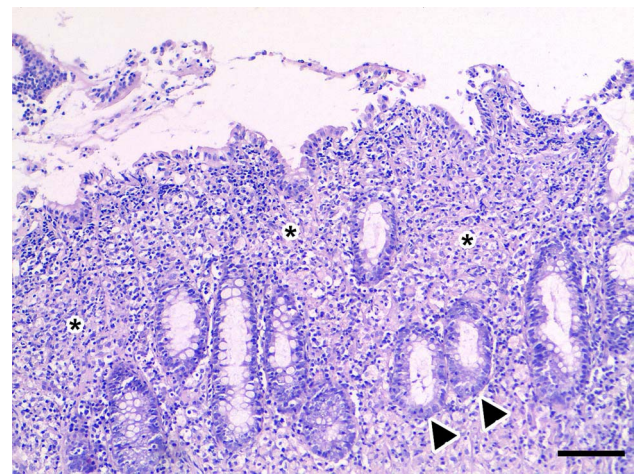


FIG 2: Histology of the colonic mucosa of a two-year-old French bulldog presented for haematochezia. Haematoxylin and eosin stained section showing infiltration of the lamina propria with large numbers of macrophages (*). Crypts (arrowheads) are reduced in number and separated by the infiltrating cells, bar=100 μ m

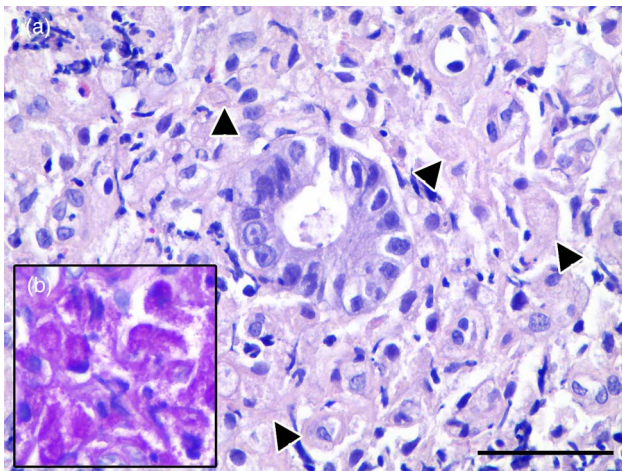


FIG 3: Higher magnification of Fig 2. (a) Macrophages (arrowheads) with abundant foamy cytoplasm. Haematoxylin and eosin stain, bar=50 µm. (b) Periodic acid-Schiff (PAS) staining highlights the presence of intracytoplasmic PAS-positive material

TREATMENT

After obtaining the bacteriological sensitivity test results, the dog was treated with 20 mg/kg amoxicillin/clavulanic acid orally three times a day (Kesium, Albrecht, Germany) for eight weeks, in combination with 8 mg/kg cefovecin subcutaneously every

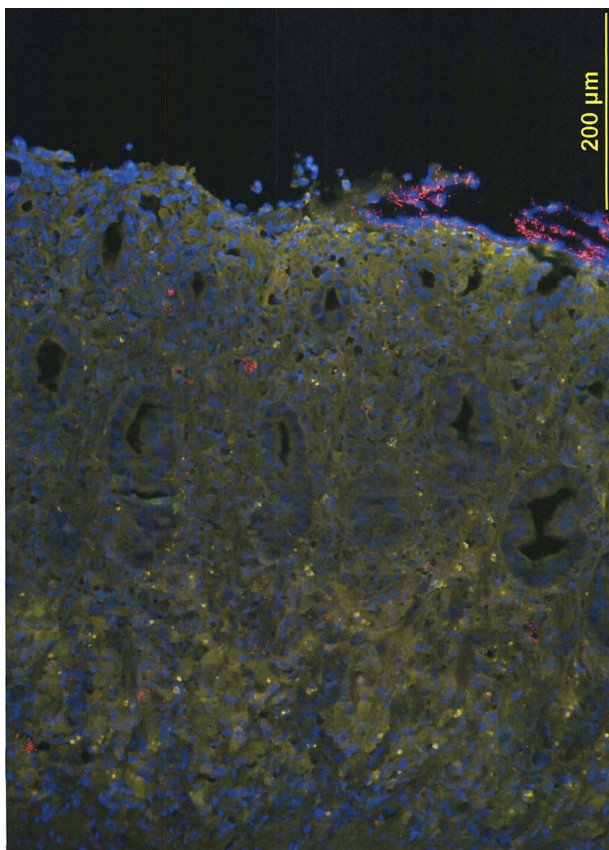


FIG 4: Fluorescence in situ hybridisation (FISH) of colonic tissue. 5Cy3-EUB-338 (red) and 56-FAM-Non-EUB-338 (green) labelled probes reveal the presence of multifocal clusters of invasive bacteria (red), which are frequently within cells. DAPI (4,6-diamidino-2-phenylindole) stained nuclei are blue

TABLE 1: Antibiotic resistance pattern of the two cultured *Escherichia coli* strains from a French bulldog with granulomatous colitis

Antibiotics	<i>E coli</i> 1	<i>E coli</i> 2
Penicillin	r	r
Doxycycline	r	r
Tetracycline	r	r
Cefalexin	r	s
Oxacillin	r	r
Chloramphenicol	r	s
Amoxicillin/clavulanic acid	s	r
Enrofloxacin	r	r
Gentamicin	s	s
Marbofloxacin	r	r
Lincomycin	r	r
Clindamycin	r	r
Sulfamethoxazole/trimethoprim	r	r
Fusidic acid	r	r
Polymyxin B	s	s
Cefovecin	r	s
Pradofloxacin	r	r
Rifampicin	r	r
Amikacin	s	s

E coli, *Escherichia coli*; r, resistant; s, sensible

10 days (Convenia, Pfizer, Germany) for seven injections. This combination was chosen to cover both *E coli* strains identified and was based on feasibility of application, owner compliance, cost and low risk of adverse effects compared with other antimicrobials like gentamicin, polymyxin B and amikacin.

OUTCOME AND FOLLOW-UP

Two weeks after starting therapy clinical signs improved and stools were soft with no haematochezia or tenesmus. Physical examination at the referring veterinary surgeon was unremarkable. One week later the dog had gained 900 g of bodyweight. CCECAI demonstrated striking clinical improvement (0 points=no evidence of disease). The dog continued to be clinically unremarkable and gained a total of 2 kg within 60 days after start of antimicrobial therapy. Treatment was continued for a total of eight weeks, and then, as the dog was still doing well, discontinued. At the time of writing this manuscript (12 months after discharge), the dog has not shown any signs indicative of a relapse and is still without any medication.

DISCUSSION

GC has previously been reported in nine French bulldogs (Van der Gaag and others 1978, Tanaka and others 2003, Krafft and others 2010, Manchester and others 2013). Initial reports documented satisfactory clinical responses and an overall good outcome in both boxers and French bulldogs with GC when treated with enrofloxacin (Hostutler and others 2004, Simpson and others 2006; Mansfield and others 2009; Manchester and others 2013). However, one study found that over 50 per cent of boxer dogs with GC harbour mucosal AIEC resistant to one or more non-fluoroquinolone antimicrobials and 43 per cent harbour fluoroquinolone-resistant *E coli* (Craven and others 2010). Antimicrobial resistance to enrofloxacin carried an extremely poor prognosis, with euthanasia of all enrofloxacin non-responders (Craven and others 2010).

Veterinary Record Case Reports

To the authors' knowledge, the present case report is the first of a French bulldog presenting with GC in Germany, and the first documenting multidrug antimicrobial resistance—including resistance to enrofloxacin—in this breed. Unfortunately, no details about the dog's pedigree or reports about the health status of littermates were available at the time.

Prior empirical treatment with enrofloxacin has been reported as a possible risk factor for acquiring resistant AIEC (Craven and others 2010). In most of the cases GC dogs tend to respond quickly (within a few weeks), hence a lack of clinical improvement to empirical fluoroquinolone therapy strongly suggests antimicrobial resistance. In these cases, (repeat) histopathology and culture from a mucosal biopsy are strongly recommended. As the dog presented here had been treated with enrofloxacin, it cannot be ruled out that this has contributed to the infiltration with multidrug-resistant *E coli*. Even though the course of treatment seemed adequate in both dosage and duration (Manchester and others 2013), making it less likely to induce resistance, previous treatment history was not completely available. Hence it cannot be excluded that prior treatments with enrofloxacin have occurred, especially as fluoroquinolones are used at an increasing frequency in veterinary medicine (Freeling and Gask 1998). A further potential explanation for the resistance of both *E coli* strains to fluoroquinolones is the inadvertent consumption of antimicrobials from the food supply for human beings and animals. In fact, fluoroquinolones have been heavily used in agriculture and aquaculture for many years (Spellberg and Doi 2015). The dramatic increase in fluoroquinolone resistance has been associated with the emergence of a specific *E coli* clone (ST 131-H30) in human medicine (Colpan and others 2013). The relevance of this clone or its occurrence in companion animals is unclear; in the present case, no phylogenetic characterisation of the isolated *E coli* strains was attempted.

The choice of antimicrobials in the presented case has to be assessed critically. The use of one antimicrobial covering both *E coli* isolates would have been ideal. Based on sensitivity testing, gentamicin, amikacin and polymyxin B were possible candidates. Aminoglycosides were not considered a good choice, as they are not able to effectively penetrate mammalian cells and are thus often ineffective in the treatment of facultative intracellular pathogens (Schwab and Mandell 1989). This is emphasised by the fact that dogs with enrofloxacin-resistant GC have not improved with aminoglycoside treatment in previous reports, even though in vitro efficacy was demonstrated (Craven and others 2010). Additionally, aminoglycosides can only be administered parenterally, restricting their use to hospitalised patients; and they have potentially serious side effects such as nephrotoxicity, ototoxicity and neurotoxicity (Plumb 2011). Polymyxin B was not an option for the dog presented here, because it is not licensed for systemic use in companion animals in Germany and can be nephrotoxic and neurotoxic. Chloramphenicol, which penetrates effectively into most tissues and has successfully been used in dogs with GC (Van Kruiningen and others 1965) was not the first choice of antimicrobial either, as both *E coli* isolates showed in vitro resistance. The same was applicable to rifampin, tetracycline, trimethoprim/sulphonamide and pradofloxacin, the antimicrobials with best efficacy for intracellular killing (Subramanian and others 2008). Further, antimicrobials like imipenem or meropenem were not tested in the sensitivity panel. Germany does not have strict antimicrobial guidelines, as, for example, some Scandinavian countries, where certain drugs are simply not available for use in animals. However, at the Small Animal Clinic it is generally considered good practice to avoid drugs

that are used as last-resort antimicrobials in human medicine. Hence, it was eventually decided to combine two β -lactam antimicrobials (a penicillin derivative and a cephalosporin), as these were the only antimicrobials available for oral and subcutaneous treatment with demonstrated in vitro efficacy. There was no evidence from the susceptibility testing that combining these with an antimicrobial of another class would be beneficial, even though synergistic effects of antimicrobial combination therapies have been reported in dogs with GC as well as in human beings with Crohn's disease (Subramanian and others 2008, Craven and others 2011). Both cephalosporins and amoxicillin/clavulanic acid are effective against infections caused by *E coli* and have few side effects (Plumb 2011). However, amoxicillin is also expected to have poor intracellular efficacy and neither of the antimicrobials chosen have been shown to accumulate within cells (Carryn and others 2003). The authors would therefore like to make a point that it should not be seen as acceptable practice to combine these antibiotics empirically. Careful consideration of antimicrobial choices is mandatory for these cases, especially if treatment failure occurs.

Fortunately, this combination led to rapid and long-standing clinical improvement in the presented case.

Some ethical concerns have to be addressed when the decision to treat infections with multidrug-resistant bacteria—especially with ESBL profiles—is made in companion animals. In human medicine, ESBL-type bacteria are responsible for a wide range of hospital-acquired infections and have been reported to be associated with a higher incidence of death (Lautenbach and others 2005). Treating multidrug-resistant infections in animals could result in increasing antibiotic resistance and transfer of multidrug resistance to human beings. As dogs often live close to human beings, their role as potential carriers of multidrug-resistant bacteria has to be assessed critically (Schauffer and others 2015). There are no firm antibiotic guidelines for these circumstances, hence the decision to treat should be made on an individual case-by-case basis, and the potential risks discussed with the owner.

Unfortunately, no follow-up biopsies for histopathology and culture were available for the dog presented here, which would be the only way to ultimately prove disease remission and the successful elimination of AIEC. However, incomplete remission with partial resolution of AIEC colonisation seems unlikely as the dog is doing well (no clinical signs) 10 months after the cessation of antibiotic treatment.

In summary, this case report shows that GC is an important differential diagnosis in French bulldogs with signs of severe colitis, even though it has so far not been reported frequently in Europe. It outlines the importance of antimicrobial susceptibility testing from colonic mucosal biopsies in these dogs. Susceptibility testing should ideally be performed before administration of antimicrobials and is indispensable in dogs with enrofloxacin-resistant GC. Clinical remission of GC is possible, even in dogs with multiresistant AIEC, hence prognosis may be favourable.

Acknowledgements FISH analysis was kindly performed by Dr KW Simpson.

Contributors MM has been primary clinician and drafted the manuscript, DPD helped with case management, MH performed the histopathological examination, RN and SS supervised the case, all authors helped to finalise the manuscript.

Competing interests None declared.

Provenance and peer review Not commissioned; externally peer reviewed.

REFERENCES

- Afshar P., Redfield D., Higginbottom P. (2010) Whipple's disease: a rare disease revisited. *Current Gastroenterology Reports* 12, 263–269

- Carryon S., Chanteux H., Seral C., Mingeot-Leclercq M. P., Van Bambeke F., Tulkens P. M. (2003) Intracellular pharmacodynamics of antibiotics. *Infectious Disease Clinics of North America* 17, 615–634
- Carvalho F. R., Kerlin R., Fredette C., Pisharath H., DebRoy C., Kariyawasam S., Pardo I. D. (2015) Histiocytic typhlocolitis in two colony Beagle dogs. *Experimental and Toxicologic Pathology* 67, 219–221
- Churcher R. K., Watson A. D. J. (1997) Canine histiocytic ulcerative colitis. *Australian Veterinary Journal* 75, 710–713
- Colpan A., Johnston B., Porter S., Clabots C., Anway R., Thao L., Kuskowski M. A., Tschesnokova V., Sokurenko E. V., Johnson J. R., VICTORY (Veterans Influence of Clonal Types on Resistance: Year 2011) Investigators (2013) *Escherichia coli* sequence type 131 (ST131) subclone h30 as an emergent multidrug-resistant pathogen among US Veterans. *Clinical Infectious Diseases* 57, 1256–1265
- Craven M., Dogan B., Schukken A., Volkman M., Chandler A., McDonough P. L., Simpson K. W. (2010) Antimicrobial Resistance Impacts Clinical Outcome of Granulomatous Colitis in Boxer Dogs. *Journal of Veterinary Internal Medicine* 24, 819–824
- Craven M., Mansfield C. S., Simpson K. W. (2011) Granulomatous colitis of boxer dogs. *The Veterinary Clinics of North America: Small Animal Practice* 41, 433–445
- Darfeuille-Michaud A., Boudeau J., Bulois P., Neut C., Glasser A. L., Barnich N., Bringer M. A., Swidsinski A., Beaugerie L., Colombel J. F. (2004) High prevalence of adherent-invasive *Escherichia coli* associated with ileal mucosa in Crohn's disease. *Gastroenterology* 127, 412–421
- Day M. J., Bilzer T., Mansell J., Wilcock B., Hall E. J., Jergens A., Minami T., Willard M., Washabau R. World Small Animal Veterinary Association Gastrointestinal Standardization Group (2008) Histopathological standards for the diagnosis of gastrointestinal inflammation in endoscopic biopsy samples from the dog and cat: a report from the World Small Animal Veterinary Association Gastrointestinal Standardization Group. *Journal of Comparative Pathology* 138(Suppl 1), S1–S43
- Freeling P., Gask L. (1998) Fluoroquinolone resistance Overuse of fluoroquinolones in human and veterinary medicine can breed resistance. *The British Medical Journal* 317, 1020–1030
- German A. J., Hall E. J., Kelly D. F., Watson A. D., Day M. J. (2000) An immunohistochemical study of histiocytic ulcerative colitis in boxer dogs. *Journal of Comparative Pathology* 122, 163–75
- Hostutler R. A., Luria B. J., Johnson S. E., Weisbrode S. E., Sherding R. G., Jaeger J. Q., Guilford W. G. (2004) Antibiotic-Responsive Histiocytic Ulcerative Colitis in 9 Dogs. *Journal of Veterinary Internal Medicine* 18, 499–504
- Jergens A. E. (2004) Clinical assessment of disease activity for canine inflammatory bowel disease. *Journal of the American Animal Hospital Association* 40, 437–445
- Krafft E., Marchal T., Guilbaud L., Hugonnard M. (2010) Colite histiocyttaire chez le chien: présentation de 3 cas cliniques. *Revue de Médecine Vétérinaire* 161, 376–380.
- Lautenbach E., Metlay J. P., Bilker W. B., Edelstein P. H., Fishman N. O. (2005) Association between fluoroquinolone resistance and mortality in *Escherichia coli* and *Klebsiella pneumoniae* infections: the role of inadequate empirical antimicrobial therapy. *Clinical Infectious Diseases* 41, 923–929
- Manchester A. C., Hill S., Sabatino B., Armentano R., Carroll M., Kessler B., Miller M., Dogan B., McDonough S. P., Simpson K. W. (2013) Association between Granulomatous Colitis in French Bulldogs and Invasive *Escherichia coli* and Response to Fluoroquinolone Antimicrobials. *Journal of Veterinary Internal Medicine* 27, 56–61
- Mansfield C. S., Jmaes F. E., Craven M., Davies D. R., O'Hara A. J., Nicholls P. K., Dogan B., McDonough S., Simpson K. W. (2009) Remission of Histiocytic Ulcerative Colitis in Boxer Dogs Correlates with Eradication of Invasive Intramucosal *Escherichia coli*. *Journal of Veterinary Internal Medicine* 23, 964–969
- Pavarini S. P., Gomes D. C., Bandinelli M. B. (2011) Colite histiocytica ulcerativa em um cão Boxer no Brasil. *Acta Scientiae Veterinariae* 39, 986.
- Plumb D. C. (2011) *Plumb's Veterinary Drug Handbook*. 7th edn. Stockholm, Wisconsin: PharmaVet Inc.
- Schaufier K., Bethé A., Lübke-Becker A., Ewers C., Kohn B., Wieler L. H., Guenther S. (2015) Putative connection between zoonotic multiresistant extended-spectrum beta-lactamase (ESBL)-producing *Escherichia coli* in dog feces from a veterinary campus and clinical isolates from dogs. *Infection Ecology & Epidemiology* 5, 25334
- Schwab J., Mandell G. (1989) The importance of penetration of antimicrobial agents into cells. *Infectious Diseases Clinics North America* 3, 461–467
- Simpson K. W., Dogan B., Rishniw M., Goldstein R. E., Klaessig S., McDonough P. L., German A. J., Yates R. M., Russell D. G., Johnson S. E., Berg D. E., Harel J., Bruant G., McDonough S. P., Schukken Y. H. (2006) Adherent and invasive *Escherichia coli* is associated with granulomatous colitis in boxer dogs. *Infection and Immunity* 74, 4778–4792
- Spellberg B., Doi Y. (2015) The Rise of Fluoroquinolone-Resistant *Escherichia coli* in the Community: Scariest Than We Thought. *Journal of Infectious Diseases* 212, 1853–1855
- Stokes J. E., Kruger J. M., Mullaney T., Holan K., Schall W. (2001) Histiocytic ulcerative colitis in three non-boxer dogs. *Journal of the American Animal Hospital Association* 37, 461–465
- Subramanian S., Roberts C. L., Hart C. A., Martin H. M., Edwards S. W., Rhodes J. M., Campbell B. J. (2008) Replication of colonic Crohn's disease mucosal *Escherichia coli* isolates within macrophages and their susceptibility to antibiotics. *Antimicrobials Agents Chemotherapy* 52, 427–434
- Tanaka H., Nakayama M., Takase K. (2003) Histiocytic Ulcerative Colitis in a French bulldog. *Journal of Veterinary Medical Science* 65, 431–433
- Van der Gaag I., Van Toorenburg J. V., Voorhout G., Happe R. P., Aalfs R. H. (1978) Histiocytic ulcerative colitis in a French Bulldog. *Journal Small Animal Practice* 19, 283–290
- Van Kruiningen H. J., Montali R. J., Strandberg J. D., Kirk R. W. (1965) A granulomatous colitis of dogs with histologic resemblance to Whipple's disease. *Veterinary Pathology* 2, 521–544.

Copyright 2016 British Veterinary Association. All rights reserved. For permission to reuse any of this content visit <http://group.bmj.com/group/rights-licensing/permissions>.

Veterinary Record Case Reports subscribers may re-use this article for personal use and teaching without any further permission.

Become a Veterinary Record Case Reports subscriber today and you can:

- ▶ Submit as many cases as you like
- ▶ Enjoy fast sympathetic peer review and rapid publication of accepted articles
- ▶ Access all the published articles
- ▶ Re-use any of the published material for personal use and teaching without further permission

For information on Institutional subscriptions contact consortia@bmj.com

Visit vetrecordcasereports.bvpublications.com for more articles like this and to become a subscriber

Favourable long-term outcome of granulomatous colitis involving two *Escherichia coli* strains with multiple antimicrobial resistances in a French bulldog in Germany

Maximilliane Mueller, Dorothee Petra Dahlem, Manfred Henrich, Reto Neiger and Silke Schmitz

Vet Rec Case Rep 2016 4:
doi: 10.1136/vetreccr-2016-000296

Updated information and services can be found at:
<http://vetrecordcasereports.bmj.com/content/4/1/e000296>

These include:

References

This article cites 27 articles, 5 of which you can access for free at:
<http://vetrecordcasereports.bmj.com/content/4/1/e000296#BIBL>

Email alerting service

Receive free email alerts when new articles cite this article. Sign up in the box at the top right corner of the online article.

Topic Collections

Articles on similar topics can be found in the following collections

[Colitis](#) (3)
[Companion or pet animals](#) (141)
[Companion or pet animals: Dogs](#) (97)
[Enteric disease](#) (8)
[Escherichia coli](#) (2)
[Gastroenterology](#) (17)
[Molecular biology](#) (4)

Notes

To request permissions go to:
<http://group.bmj.com/group/rights-licensing/permissions>

To order reprints go to:
<http://journals.bmj.com/cgi/reprintform>

To subscribe to BMJ go to:
<http://group.bmj.com/subscribe/>